

REGRESSION OF OSTEOGENIC SARCOMA METASTASES ASSOCIATED WITH INTENSIVE MEDITATION

Med. J. Aust., 1978, 2: 433.

THE PATIENT, aged 25, underwent a mid-thigh amputation for osteogenic sarcoma 11 months before he first saw me 2½ years ago. He had visible bony lumps of about 2 cm in diameter growing from the ribs, sternum and the crest of the ilium, and was coughing up small quantities of blood in which, he said, he could feel small spicules of bone. There were gross opacities in the X-ray films of his lungs. The patient had been told by a specialist that he had only two or three weeks to live, but in virtue of his profession he was already well aware of the pathology and prognosis of his condition. Now, 2½ years later, he has moved to another State to resume his former occupation.

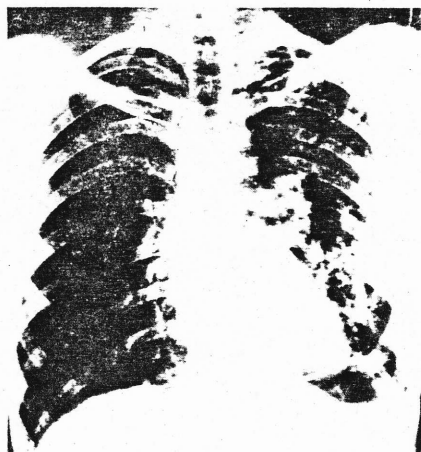

FIGURE 1: Chest X-ray film taken on October 19, 1976.

This young man has shown an extraordinary will to live, and has sought help from all the alternatives to orthodox medicine which were available to him. These have included acupuncture, massage, several sessions with Philippine faith healers, laying on of hands and yoga in an

Address for reprints: Dr Ainslie Meares, 99 Spring Street, Melbourne, Vic. 3000

Indian ashram. He had short sessions of radiation therapy, and chemotherapy, but declined to continue treatment. He has also persisted with the dietary and enema



FIGURE 2: Photograph of the patient's chest which was taken on July 7, 1977.

treatment described by Max Gerson, the German, physician, who gained some notoriety for this type of treatment in America in the 1940s.¹ However, in addition

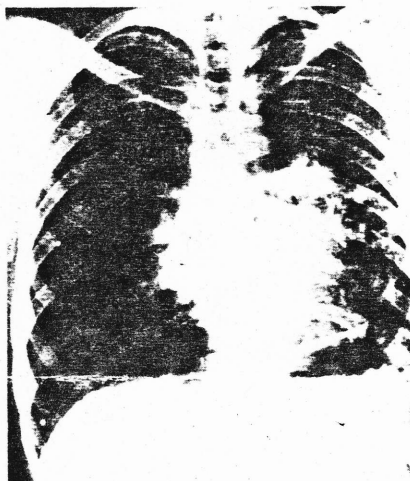


FIGURE 3: Chest X-ray film taken on January 1, 1978.

to all these measures to gain relief, the patient has consistently maintained a rigorous discipline of intensive meditation as described previously.² He has, in fact,

consistently meditated from one to three hours daily.

Two other factors seem to be important. He has had extraordinary help and support from his girl friend, who more recently became his wife. She is extremely sensitive to his feelings and needs, and has spent hours in aiding his meditation and healing with massage and laying on of hands.



FIGURE 4: A recent photograph of the patient's chest.

The other important factor would seem to be the patient's own state of mind. He has developed a degree of calm about him which I have rarely observed in anyone, even in oriental mystics with whom I have had some considerable experience. When asked to what he attributes the regression of metastases, he answers in some such terms as: "I really think it as our life, the way we experience our life". In other words, it would seem that the patient has let the effects of the intense and prolonged meditation enter into his whole experience of life. His extraordinarily low level of anxiety is obvious to the most casual observer. It is suggested that this has enhanced the activity of his immune system by reducing his level of cortisone.

99 Spring Street. AINSLIE MEARES,
Melbourne, Vic. 3000. M.D., D.P.M.

[Since this report was written the patient has been declared free of active neoplastic disease — A.M.]

REFERENCES

¹ GERSON, M. *A Cancer Therapy*. 2nd ed. Totality Books, Del Mar, California, 1975.

² MEARES, A. Atavistic regression as a factor in the remission of cancer. *Med. J. Aust.*, 1977, 2: 132.